

# A case of fourth head of triceps brachii

Pratik Khona, Samita Rani, Umesh Kulkarni

Department of Anatomy, Belagavi Institute of Medical Sciences, Belagavi, Karnataka, India

## Abstract

The variations of Triceps Brachii, the sole muscle of the posterior compartment of the arm, though rare have been mentioned in the literature - commonest being the fourth head of origin of the muscle. One such variation was found during routine dissection for undergraduate students in a left arm of a male cadaver at Department of Anatomy, Belagavi Institute of Medical Sciences, Belagavi. The muscle had a fourth head which originated from the posterior part of capsule of shoulder joint just above the surgical neck of humerus. The muscle belly was fleshy throughout its course and fused with the long head of triceps around the junction of upper and middle one third of humerus. The embryological basis, comparative anatomy and clinical significance of such variation will be discussed in detail.

**Key words:** Triceps brachii, Variations, Fourth head

## Introduction

Although variations of triceps brachii muscle are relatively less common, they have at times been reported by various authors. Triceps brachii is a muscle of extensor compartment of the arm. It fills most of the compartment and arises by three heads (long, lateral and medial), from which it takes its name. The long head arises by a flattened tendon from the infraglenoid tubercle of the scapula, blending above with the glenohumeral capsule, the lateral head arises by a flattened tendon from a narrow, linear, oblique ridge on the posterior surface of the humeral shaft above the radial groove and the medial head takes its origin from entire posterior surface of the humeral shaft below the radial groove<sup>1</sup>. Some additional heads other than these have been encountered previously. In this case we found a fourth head of the muscle arising from posterior part of capsule of the shoulder joint. Comparison of findings of this case with previously found variations by different authors and the possible embryological and comparative anatomical basis for the same has been discussed in the article.

## Case report

During routine cadaveric dissection for undergraduates in Department of Anatomy, Belagavi Institute of Medical Sciences, Belagavi, we found a fourth head of triceps brachii muscle in left upper arm of a male

cadaver. The muscle belly was neatly dissected and its measurement and photographs were taken.

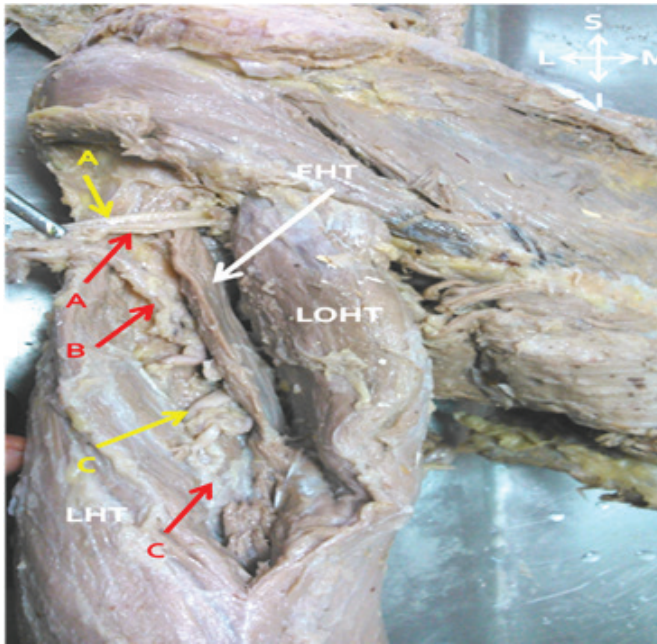
The fourth head was taking its origin from the posterior part of the capsule of the shoulder joint just above the surgical neck of the humerus, and lateral to the long head of the muscle. The muscle belly then descended inferomedially and joined with the long head just before it formed the common tendon with the lateral head of the triceps. The fourth head was muscular throughout and no tendon was found (Figure 1). The muscle belly was measuring 9.5 cms. It received its nerve supply from a separate branch from the branch of radial nerve supplying the long head. The axillary nerve and the posterior circumflex humeral vessels traversed between the long and the fourth head and the muscle belly of fourth head crossed above the profunda brachii artery and radial nerve in the radial groove. No other variations were found on both the upper limbs.

## Address for Correspondence

**Dr. Pratik Khona**

Post graduate student, Dept. of Anatomy, Belagavi Institute of Medical Sciences, Belagavi-590001, Karnataka, India.

E-mail: drpratikkhona@gmail.com



**Figure 1. Fourth head of triceps with its relations**

(A - Axillary Nerve & Post Circumflex Humeral Artery, B - Communicating artery, C- Radial Nerve & Profunda Brachii Artery, LHT - Lateral Head of Triceps, LOHT - Long Head of Triceps, FHT - Fourth Head of Triceps)

#### DISCUSSION:

Triceps brachii muscle normally has three heads. The long head originates from the infraglenoid tubercle, the lateral head from the humerus superior to the radial groove and lateral intermuscular septum and the medial head from the humerus inferior to the radial groove and medial intermuscular septum. Majority of the muscle inserts onto the olecranon process and contributes to the extension of forearm. It is supplied by a branch from the radial nerve and profunda brachii artery<sup>1</sup>. The fibres of the medial head of triceps brachii are inserted partly into the olecranon process of ulna and partly into posterior part of the capsule of the elbow joint. The attachment of the capsule of elbow joint prevents from being nipped in the extension of the elbow joint. This part of the medial head, therefore, can be called articularis genu of upper limb, similar to that of the lower limb<sup>2</sup>.

Triceps brachii muscle show many variations. Each of the heads may be fused, in varying degrees, with neighboring muscles. The fibers of the long head may extend to the capsule of the shoulder joint above or distally, for a greater extent than usual on the axillary border of the scapula. Macalister described the variations of triceps brachii as follows:

- It may have a fourth head from the medial part of the humerus below the head, by a long, slender tendon, and by an aponeurotic expansion from the capsule of the shoulder - this head blended with the inner (medial) head;
- Macalister has frequently seen the long head split, one attached to the capsule, and the other to the tricipital spine, axillary border, or the first slip was found splitting the capsular ligament, like the curved head of rectus femoris;
- The existence of a slip from the tendon of latissimus dorsi has been seen several times. It was described by Bergman in 1855; and it was also mentioned by Halbertsma under the name of anconeus quintus; this may occasionally come from the teres major<sup>3</sup>.

A fourth head of triceps may arise from different points on the humerus, scapula, shoulder joint capsule or the coracoid process<sup>4</sup>. Fabrizio and Clemente demonstrated a single tendon arising from the proximal posteromedial aspect of the shaft of humerus, distal to the shoulder capsule. The tendon of this fourth head passed along the medial aspect of the humerus and gave way to a muscle belly on the medial surface of the distal one-third of the humerus<sup>5</sup>. Ipsilateral four-headed triceps brachii muscle was found by Tubbs et al. They reported an additional attachment site of the medial head of the triceps brachii. This head originated from the posterior aspect of the surgical neck of the humerus<sup>6</sup>. Cheema and Singla also found extra head of triceps brachii muscle originating from humerus from the medial side of surgical neck of humerus, the muscle belly of extra head was blending with the long head of triceps brachii muscle<sup>7</sup>. R Kulkarni, R. N. Kulkarni and S Solan found the fourth head of triceps brachii was arising from the upper part of the posterior aspect of the shaft of the humerus immediately below the capsule of the shoulder joint and from the upper part of the oblique line along with lateral head of triceps brachii. The origin was by a long tendon which extended on the medial aspect of arm after crossing the radial nerve and profunda brachii vessels superficially along with the lateral head of triceps brachii. In the lower one third of the posterior aspect of the arm the tendon continued as muscular belly which merged with the medial part of medial head of triceps brachii<sup>8</sup>. P Sonje, P Vatsalaswamy and V Arole found a single tendon which was seen being attached to the posteromedial aspect of upper part of the shaft of humerus close to surgical neck above radial groove and was running close to medial side of the shaft of humerus over the neurovascular bundle,

containing radial nerve and profunda brachii artery and its muscle belly was merging with the medial head of triceps brachii<sup>9</sup>.

In this case the fourth head resembles the one described by Cheema and Singla except that the head was made up of muscle belly throughout its course. The fourth head did pass on the neurovascular bundle and hence can be a cause of compression of the same in strenuous physical work or muscular contraction and lead to neurovascular compromise. Embryologically, the first indication of limb musculature is observed in the seventh week of development as a condensation of mesenchyme near the base of the limb buds. As in other regions, connective tissue dictates the pattern of muscle formation. With elongation of the limb buds, the muscle tissue splits into flexor and extensor components. As soon as the buds form, ventral primary rami from the appropriate spinal nerves penetrate into the mesenchyme. Immediately after the nerves have entered the limb buds, they establish an intimate contact with the differentiating mesodermal condensations<sup>10</sup>. The triceps muscle is derived from the extensor component and it could be that during this period the accessory muscles may have formed. Or otherwise as in this case the axillary nerve and posterior circumflex vessels might have separated the fourth head from the long head of triceps brachii.

Comparative anatomically, the triceps brachii muscle in carnivores is bulky and is made up of many sub heads of the muscle:

- Long head has – anterior and posterior parts. Branches of the profunda brachii artery and vein pass out between these two parts
- Medial head has – small- intermediate and long heads.
- Lateral head

The components of Medial head those are, the long head, separable from the triceps lateralis only for a very short distance after its origin, which is from a triangular area on the posterior surface of the shaft of the humerus, beginning at the lip of the articular surface, the most superficial fibers arising from the joint capsule and the intermediate head, it takes a tendinous origin from a short line on the postero-medial edge of the shaft of the humerus, immediately beneath and behind the insertion of the latissimus tendon<sup>11</sup>. According to this the present case may be non fusion of these to heads during evolution.

**Conclusion:** The fourth head of the triceps brachii muscle may be seen due to the following probable causes-

- Embryologically, while differentiation of the musculature if there is any connective tissue or neurovascular bundle interfering in its development
- If Evolutionary fusion or disappearance of the sub heads of the three heads of the triceps brachii muscle is not completed.

In this case as the muscle belly is being supplied by the branch from the radial nerve supplying the long head, we would suggest it to be the former cause as the axillary nerve and posterior circumflex humeral artery separate the fourth head from the long head.

If the fourth head is tendinous then it passing over the neurovascular bundle can cause compression of the same in strenuous exercise and work like weightlifting, which is not seen in this case.

## References

1. William PL, Bannister LH, Berry MM, Collins P, Dyson M, Dussek JE, Ferguson MWJ. *Gray's Anatomy*. 38th Ed. New York: ELBS, Churchill Livingstone; 1995.
2. R. J. Last. *Anatomy – Regional and Applied*. 7th Edition, New York: ELBS, Churchill Livingstone; 1985.
3. Bergman RA, Afifi AK, Miyauchi R. *Illustrated Encyclopedia of Human Anatomic Variation: Opus I: Muscular System : Alphabetical Listing of Muscles: T, Triceps Brachii*. Available at: <http://www.anatomyatlases.org/AnatomicVariants/MuscularSystem/Text/T/47Triceps.shtml> (Accessed 9th May 2016)
4. Anson BJ. *Morris' Human Anatomy*. 12th Ed. New York: McGraw-Hill; 1966.
5. Fabrizio PA, Clemente FR. *Variation in the triceps brachii muscle: a fourth muscular head*. *Clinical Anatomy* 1997; 10: 259-263.
6. Shane Tubbs R, George Salter E, Jerry Oakes W. *Triceps brachii muscle demonstrating of fourth head*. *Clinical Anatomy*: 2006; 19: 657 – 666.
7. Cheema P, Singla R. *Four headed triceps brachii muscle*. *International Journal of Anatomical Variations (IJAV)*. 2011; 4: 43-44.
8. Kulkarni R, Kulkarni RN, Solan S. *Unilateral right quadriceps brachii – a case report*. *Anatomica Karnataka*. 2012; 6: 15-17.
9. Sonje P, Vatsalaswamy P, Arole V. *Fourth head of triceps brachii muscle – a case report*. *International Journal of Anatomical Variations (IJAV)*. 2013; 6: 167 - 169.
10. Sadler TW. *Langman's Medical Embryology – In Muscular System*. 10th Edition. New York: Lippincott, Williams and Wilkins; 2006. p. 146-147.
11. Dwight Davis D. *The shoulder architecture of bears and other carnivores*. *Chicago Natural History Museum* 1949; 31 16: 34.

Conflict of interest: **Nil**

Source of funding: **Nil**

Date received: September 26<sup>th</sup> 2016

Date accepted: December 10<sup>th</sup> 2016